

See discussions, stats, and author profiles for this publication at: <https://www.researchgate.net/publication/338335218>

# Progressive Enlarging Blind Spot in a Young Asian Lady: A Case Report on Acute Zonal Occult Outer Retinopathy

Article in *Gazi Medical Journal* · January 2020

DOI: 10.12996/gmj.2020.18

CITATIONS

0

READS

26

4 authors, including:



**Alvin Oliver Payus**

Universiti Malaysia Sabah (UMS)

17 PUBLICATIONS 2 CITATIONS

[SEE PROFILE](#)



**Constance Liew Sat Lin**

Universiti Malaysia Sabah (UMS)

19 PUBLICATIONS 3 CITATIONS

[SEE PROFILE](#)



**Malehah Mohd Noh**

Universiti Malaysia Sabah (UMS)

7 PUBLICATIONS 1 CITATION

[SEE PROFILE](#)

Some of the authors of this publication are also working on these related projects:



Case report [View project](#)



Critical Care Anaesthesia [View project](#)

## Progressive Enlarging Blind Spot in a Young Asian Lady: A Case Report on Acute Zonal Occult Outer Retinopathy

Genç Asyalı Bir Kadında Progresif Büyüyen Kör Nokta: Akut Zonal Gizli Gizli Retinopatiye İlişkin Bir Olgu Sunumu

Alvin Oliver Payus<sup>1</sup>, Ang Wen Jeat<sup>2</sup>, Liew Sat Lin<sup>1</sup>, Malehah Mohd Noh<sup>1</sup>

<sup>1</sup>Faculty of Medicine and Health Science, Universiti Malaysia Sabah (UMS), Jalan UMS, 88400 Kota Kinabalu, Sabah, Malaysia

<sup>2</sup>Ophthalmology Department, Melaka General Hospital, Jalan Mufti Haji Khalil, 75400 Melaka City, Melaka, Malaysia

### ABSTRACT

Acute Zonal Occult Outer Retinopathy (AZOOR) is a very rare retinal disease that predominantly affect the Caucasians. It is usually present in a young myopic woman with an acute onset of photopsia and enlarging blind spots. Here, we report a young Asian lady who presented with a typical presentation of AZOOR and later confirmed by electrophysiological test of the retina. She was wrongly diagnosed as retrobulbar optic neuritis due to low index of suspicion for AZOOR among the treating physicians in the hospital. Fortunately, she responded to systemic corticosteroid that was given as a treatment of optic neuritis. AZOOR was only diagnosed later by a visiting European neuro-ophthalmologist in a neighbouring country. The objective of this case report is to remind the reader that the condition exists in Asian population and should be kept as a differential diagnosis in a young lady who presented with progressive visual field defect.

**Key Words:** Acute Zonal Occult Outer Retinopathy; Enlarging blind spots; Optic neuritis; systemic corticosteroid

**Received:** 01.19.2019

**Accepted:** 11.20.2019

### ÖZET

Akut Zonal Okült Dış Retinopati (AZOOR), çoğunlukla Kafkasyalıları etkileyen çok nadir görülen bir retina hastalığıdır. Genellikle akut bir fotopsi başlangıcı ve genişleyen kör noktaları olan genç bir miyop kadında bulunur. Burada, tipik bir AZOOR sunumu ile başvuran ve daha sonra retinanın elektrofizyolojik testi ile onaylanan genç bir Asyalı kadını rapor ediyoruz. Hastanede tedavi gören doktorlar arasında AZOOR için düşük şüphe indeksi nedeniyle yanlış bir retrobulbar optik nörit tanısı aldı. Neyse ki, optik nörit tedavisi olarak verilen sistemik kortikosteroid yanıt verdi. AZOOR, daha sonra komşu bir ülkede ziyaret eden Avrupalı nöro-oftalmolog tarafından teşhis edildi. Bu vaka raporunun amacı, okuyucuya durumun Asya popülasyonunda var olduğunu ve ilerici görme alanı kusuru ile başvuran genç bir bayanda ayırıcı tanı olarak saklanması gerektiğini hatırlatmaktır.

**Anahtar Sözcükler:** Akut Zonal Gizli Gizli Retinopati; Kör noktaları büyötmek; Optik nörit; sistemik kortikosteroid

**Geliş Tarihi:** 19.01.2019

**Kabul Tarihi:** 20.11.2019

**ORCID IDs.:** A.O.P. 0000-0003-4675-103X, A.W.J. 0000-0002-8112-2258, L.S.L. 0000-0003-2474-6598, M.M.N. 0000-0002-8166-7119

**Address for Correspondence / Yazışma Adresi:** Alvin Oliver Payus, MD Faculty of Medicine and Health Science, Universiti Malaysia Sabah (UMS), Jalan UMS, 88400 Kota Kinabalu, Sabah, Malaysia E-mail: dralvinpayus@ums.edu.my

©Telif Hakkı 2020 Gazi Üniversitesi Tıp Fakültesi - Makale metnine <http://medicaljournal.gazi.edu.tr/> web adresinden ulaşılabilir.

©Copyright 2020 by Gazi University Medical Faculty - Available on-line at web site <http://medicaljournal.gazi.edu.tr/>

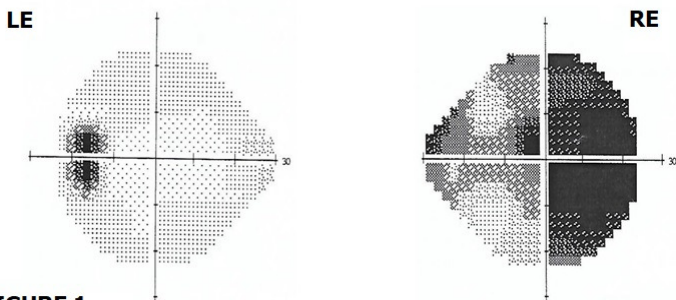
doi:<http://dx.doi.org/10.12996/gmj.2020.18>

**INTRODUCTION**

Acute Zonal Occult Outer Retinopathy (AZOOR) is a rare condition of retinal dysfunction characterized by focal degeneration of the peripheral photoreceptor that was first described in 1993 by J. D Gass *et al.* (1) It is clinically manifested as sudden onset of photopsia, photophobia and enlarging blind spots in a myopic young woman. In this report, our patient who is a young Asian lady who presented with acute enlarging blind spot and other typical presentation of AZOOR, and later confirmed by electrophysiological test which consistent with AZOOR. And this rare condition will be the centre of discussion in this case report.

**CASE REPORT**

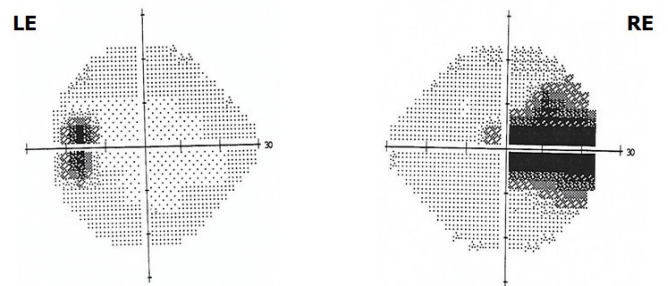
A 32-years old lady presented with a sudden onset of patchy loss of vision over the right eye which was associated with feeling of dry eye that occur after she woke up from sleep. She denied any recent history of trauma, fever, eye pain or discharge, eye redness or any recent corneal illness. She had an episode of transient, self-limiting patchy visual loss over the upper nasal field of the right eye for 2 days that occur 2 years ago, in which she did not seek any medical attention. For her current presentation, eye examination reveals normal visual acuity, no significant changes on fundoscopy, and no evidence of relative afferent pupillary defect (RAPD). Therefore, she was discharge and treated with eye drops. Overnight, her condition deteriorates with worsening of pain and enlarging of visual field loss. Fundoscopy reveals hyperaemic retina with blurring of optic disc margin over the nasal side, with some vitreous condensation over the right eye. The impression at that time was retrobulbar optic neuritis of the right eye. She was the subjected for Humphrey Visual Field test, which reveal loss of visual field over the right eye. Her left eye was otherwise normal (as shown in Figure 1).



**FIGURE 1**

**Figure 1:** Humphrey Visual Field Test of the left (LE) and right eye (RE). This was done during her first admission. LE is normal. RE show reduced peripheral and central visual field, with more prominent over the periphery.

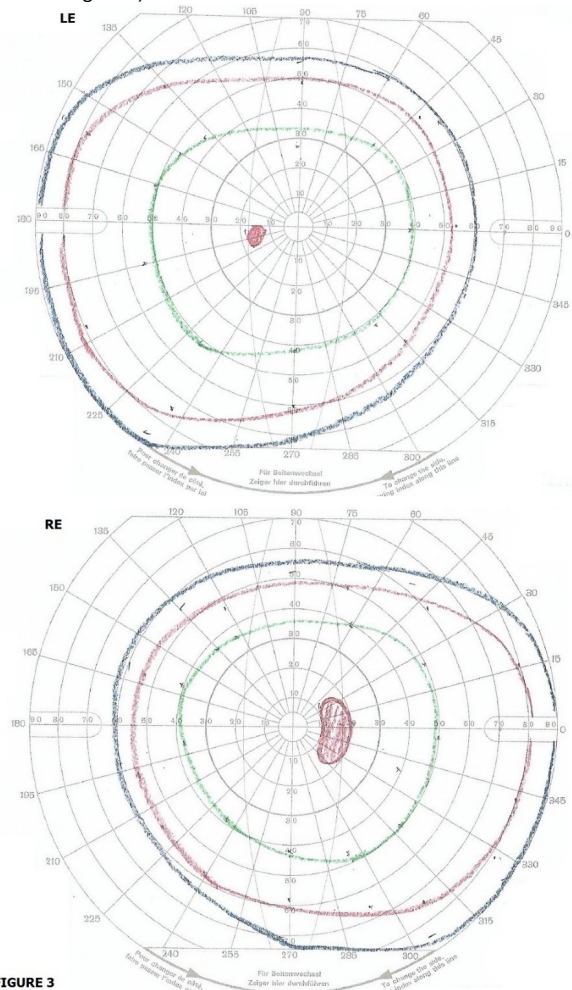
Red desaturation test showed 50% reduction from normal. She was treated with intravenous Methylprednisolone 250mg four times a day for 3-days, then continue with Tab. Prednisolone 60mg once daily for 11-days. During the first 3-days of her treatment, the peripheral visual field of her right eye continued to worsened with reduction of 20% of normal field. The centre vision was never affected, as well as her left eye. Her condition started to improve after completed 14 days of steroid therapy. On her first clinic review one month after presentation, the right eye visual field had improved but still reduced, giving ‘tunnelled- vision’ and peripheral visual field images were blur (right eye normal vision about 40% of normal visual field). Her red desaturation test has also improved to about 70% of a normal eye. She repeated a Humphrey Visual Field test and it show improvement of the right visual field (as shown in Figure 2).



**FIGURE 2**

**Figure 2:** Humphrey Visual Field Test of the left (LE) and right eye (RE). This repeated test was done 1-month after the previous one. LE is normal. RE still show reduced peripheral visual field. The central visual field improved compared to previous test.

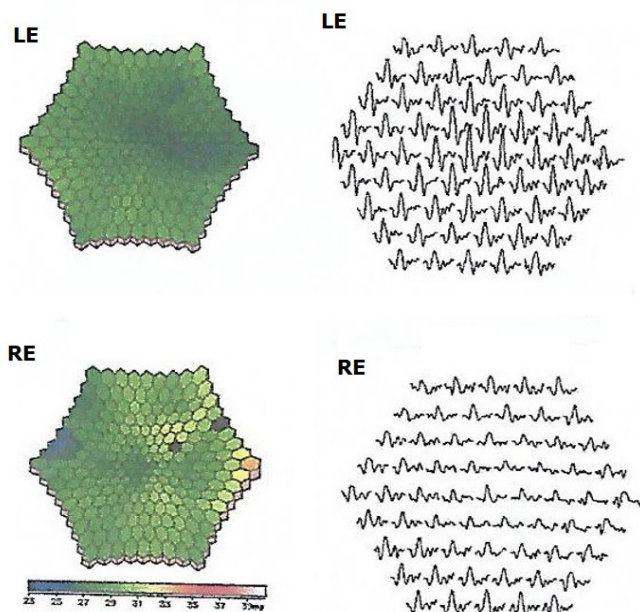
However, she started to see flashes of light and developed photophobia. Laboratory investigations to rule out other possible causes of optic neuritis, both infective and non-infective were also done and came back negative. These include Leptospira and Measles serology, and autoantibody screen namely antinuclear antibody, rheumatoid factor antibody, anti-double stranded DNA antibody, lupus anticoagulant and aquaporin-4 antibody. Magnetic Resonance Imaging of the brain and orbit was normal. The patient seeks second opinion from an oversea eye specialist centre one month after the presenting complaint. She was subjected to Goldmann Visual Field test, which showed enlarged blind spot over the right eye and normal left eye (as shown in Figure 3).



**FIGURE 3**

**Figure 3:** Goldmann Visual Field Test of the left (LE) and right eye (RE). This was done 1-month after the presenting complaint. It shows normal LE and enlarged blind spot over the RE.

She also undergone visual electrophysiology test at that centre on the same time. The test of the right eye reveals a reduced amplitude in the pattern electroretinogram (ERG) which suggestive of abnormal macular function. The ratio between N95 and P50 component of pattern ERG was within the normal limit which suggestive of normal optic nerve function. The pattern visual evoked potential was also not delayed as one would expect in optic neuritis. The scotopic (rod-derived) and the maximal (mixed rod-cone) responses of the full-field ERG were within lower limit of normal range and reduced in comparison to the left eye. The photopic (cone-derived) responses were markedly reduced in amplitude. The multifocal ERG responses were reduced in all 4 central rings and not just limited to blind spots (as shown in Figure 4). All the test parameters are within the normal range over the left eye.



**FIGURE 4**

**Figure 4:** Multifocal electroretinogram test of the left (LE) and right eye (RE). This was done 1-month after the presenting complaint. The LE was normal. The RE shows reduced response in all four central rings and not just limited to blind spot.

All these findings were in keeping with the diagnosis of Acute Zonal Occult Outer Retinopathy (AZOOR) in which she finally arrived. However, currently there is no evidence of any effective treatment for AZOOR. Fortunately, the patient has showed excellent recovery on her regular followed up in the clinic. Her latest review shown that the visual acuity remains normal, photophobia and photopsia remain static, the peripheral visual field defect of the right eye improved to about 60% of a normal eye, but reduced to 40% under bright environment. The red desaturation test improved to 80 to 90% of a normal eye.

## DISCUSSION

Acute Zonal Occult Outer Retinopathy (AZOOR) is a very rare retinal dysfunction characterized by focal degeneration of the peripheral photoreceptor that was first described by J. D Gass *et al* in 1993. (1) This condition is thought to occur in response to inflammatory process based on the observed blood flow changes in the choroid that showed inflammatory pattern (2) and resulted in secondary impairment of the photoreceptor in the outer segments. In general, AZOOR typically occur in a young female who has high myopia and present with acute onset of unilateral or bilateral visual disturbances characterized by photopsia, photophobia and visual field defect in an apparently normal or minimal fundoscopic changes. The visual field defects are commonly enlarged blind spots or scotoma connecting to the blind spots.

The prognosis of AZOOR is variable. According to Gass *et al*. (2002), 26% of the cases they observed showed improvement, while 19% showed deterioration. (3) As AZOOR predominantly occur in the Caucasian population, it is expected that most literatures are centred around the Caucasian population. There are only a few published case reports and small

size case series that described the occurrence of AZOOR and their outcomes among Asian populations. (4) Song ZM *et al*. (2008) who studied the clinical characteristics of AZOOR in Chinese patients reported that female gender, photopsia, visual field defect, ERG abnormality and minimal fundoscopic changes are the common presentation in Chinese AZOOR patients. A retrospective study done by Saito S. *et al*. (2015) reported that the visual outcome in Japanese AZOOR patients was good. Most of the patients had good visual acuity at presentation and showed spontaneous regression. And the patient who had progressive visual impairment during initial presentation, the visual function improved after systemic corticosteroid therapy. According to Bae KW *et al*. (2016) who studied 13 AZOOR patients who visited Seoul National University Bundang Hospital, all of them have visual field defect upon presentation, half of the patients showed visual field recovery, and 20% showed progression. (5-7)

There is no one single treatment to date has been shown to be effective in treating AZOOR. The therapeutic response of systemic corticosteroid or other forms of immunosuppressants had only been sporadically reported in the literature. In a retrospective study by Chen SN *et al*. (2015), they found that systemic corticosteroid therapy seems to improve the visual outcome of AZOOR. However, the study suffers a few limitations like small sample size and limited control group. (8) A case report by Kitakawa *et al*. (2012) described a dramatic improvement of visual acuity and visual field after pulse steroid therapy in one AZOOR patient. (9)

In this report, our patient was initially missed diagnosed as retrobulbar optic neuritis as a result of low suspicion index among the treating physicians. This may be due to their unfamiliarity of the condition. Fortunately for the patient that after she given a high dose systemic corticosteroid as a treatment for acute optic neuritis, her visual field defect improved. However, sadly that she only arrived to the diagnosis of AZOOR when she was seen by a visiting European ophthalmologist in a neighbouring country. This case report suffers one major limitation which is lack of important figures to show especially the fundal image during initial presentation, like the fundus autofluorescence, optical coherence tomography, fluorescence angiography and others. However, the author believe that this case report still able to serve its purpose to illustrate the common pitfall that a not-well informed physician will do when they encounter a patient that present with the symptoms as such.

## CONCLUSION

This case report serves to remind the reader that AZOOR can occur in a non-white Asian population, and thus to keep the diagnosis under consideration whenever a young lady who presented with unilateral or bilateral visual field defect associated with photopsia and photophobia but otherwise normal visual acuity and fundal examination, in order to prevent diagnostic delay.

## Conflict of interest

No conflict of interest was declared by the authors.

## REFERENCES

- Gass JD. Acute zonal occult outer retinopathy. Donders Lecture: The Netherlands Ophthalmological Society, Maastricht, Holland, June 19, 1992. *J Clin Neuroophthalmol*. 1993; 13: 79-97.
- Saito M, Saito W, Hashimoto Y, *et al*. Correlation between decreased choroidal blood flow velocity and the pathogenesis of acute zonal occult outer retinopathy. *Clin Experiment Ophthalmol*. 2014; 42: 139-50.
- Gass JD, Agarwal A, Scott IU. Acute zonal occult outer retinopathy: a long-term follow-up study. *Am J Ophthalmol*. 2002;134:329-39.
- Monson DM, Smith JR. Acute zonal occult outer retinopathy. *Surv Ophthalmol*. 2011; 56: 23-35. doi:10.1016/j.survophthal. 2010.07.004
- Bae KW, Park KH, Woo SJ, Hwang JM. Clinical Characteristics of Acute Zonal Occult Outer Retinopathy. *J Korean Ophthalmol Soc*. 2016;57:413-9.
- Saito S, Saito W, Saito M, *et al*. Acute zonal occult outer retinopathy in Japanese patients: clinical features, visual function, and factors affecting visual function. *PLoS one*. 2015 Apr 28;10:e0125133.
- Song ZM, Sheng YJ, Chen QS, *et al*. Clinical characteristics of acute zonal occult outer retinopathy in Chinese patients. *Ophthalmologica*. 2008;222:149-56.
- Chen SN, Hwang JF. Ocular coherence tomographic and clinical characteristics in patients of punctuate inner choroidopathy associated with zonal outer retinopathy. *Ocular immunology and inflammation*. 2014 Aug 1;22:263-9.
- Kitakawa T, Hayashi T, Takashina H, *et al*. Improvement of central visual function following steroid pulse therapy in acute zonal occult outer retinopathy. *Doc Ophthalmol*. 2012;124:249-54.