

See discussions, stats, and author profiles for this publication at: <https://www.researchgate.net/publication/341940828>

RECTAL FOREIGN BODIES: SEXUAL GRATIFICATION TURNED MISERY

Article in *Brunei International Medical Journal* · June 2020

CITATIONS

0

READS

25

5 authors, including:



Chiak Yot Ng

Universiti Malaysia Sabah (UMS)

4 PUBLICATIONS 0 CITATIONS

[SEE PROFILE](#)



Firdaus Hayati

Universiti Malaysia Sabah (UMS)

118 PUBLICATIONS 46 CITATIONS

[SEE PROFILE](#)



Aishath Azna Ali

Hospital Universiti Kebangsaan Malaysia (HUKM)

14 PUBLICATIONS 9 CITATIONS

[SEE PROFILE](#)



Mohd Firdaus Che Ani

Universiti Teknologi MARA

29 PUBLICATIONS 3 CITATIONS

[SEE PROFILE](#)


Some of the authors of this publication are also working on these related projects:



ERAS project [View project](#)



Pathology [View project](#)



OFFICIAL PUBLICATION OF
THE MINISTRY OF HEALTH,
BRUNEI DARUSSALAM

Brunei International Medical Journal

Volume 16

5 June 2020 (13 Syawal 1441H)

RECTAL FOREIGN BODIES: SEXUAL GRATIFICATION TURNED MISERY.

Chiak Yot NG¹, Firdaus HAYATI², Aishath Azna ALI³, Mohd Firdaus CHE ANI⁴, Andee Dzulkarnaen ZAKARIA⁵

¹Department of Medicine, and ²Department of Surgery, Faculty of Medicine and Health Sciences, Universiti Malaysia Sabah, Kota Kinabalu, Sabah, Malaysia.

³Department of Surgery, Indira Gandhi Memorial Hospital, Male', Republic of Maldives

⁴Department of Surgery, Faculty of Medicine, Universiti Teknologi MARA, Selangor, Malaysia.

⁵Department of Surgery, School of Medical Sciences, Universiti Sains Malaysia, Kelantan, Malaysia.

ABSTRACT

Receiving referrals for a retained foreign body in the lower gastrointestinal tract is not something rare these days. Foreign body insertion can be classified as voluntary or involuntary which might present to the emergency department for assistance with removal. We describe a 25-year-old lady with abdominal pain and per-rectal bleeding after a retained foreign body in the rectum. She denied any peculiar activities but confessed after pelvic radiograph suggested a foreign body likely represents a self-inserted material in the rectum. Patients may present with a wide variety of symptoms but typically the history will be misleading fearing of prejudice and discrimination from the mainstream treatment. We highlight our surgical intervention and its literature review.

Keywords: Abdominal radiography, Foreign bodies, Laparotomy, Sexual orientation.

Brunei Int Med J. 2020;16:73-76

RECTAL FOREIGN BODIES: SEXUAL GRATIFICATION TURNED MISERY.

Chiak Yot NG¹, Firdaus HAYATI², Aishath Azna ALI³, Mohd Firdaus CHE ANI⁴, Andee Dzulkarnaen ZAKARIA⁵

¹Department of Medicine, and ²Department of Surgery, Faculty of Medicine and Health Sciences, Universiti Malaysia Sabah, Kota Kinabalu, Sabah, Malaysia.

³Department of Surgery, Indira Gandhi Memorial Hospital, Male', Republic of Maldives

⁴Department of Surgery, Faculty of Medicine, Universiti Teknologi MARA, Selangor, Malaysia.

⁵Department of Surgery, School of Medical Sciences, Universiti Sains Malaysia, Kelantan, Malaysia.

ABSTRACT

Receiving referrals for a retained foreign body in the lower gastrointestinal tract is not something rare these days. Foreign body insertion can be classified as voluntary or involuntary which might present to the emergency department for assistance with removal. We describe a 25-year-old lady with abdominal pain and per-rectal bleeding after a retained foreign body in the rectum. She denied any peculiar activities but confessed after pelvic radiograph suggested a foreign body likely represents a self-inserted material in the rectum. Patients may present with a wide variety of symptoms but typically the history will be misleading fearing of prejudice and discrimination from the mainstream treatment. We highlight our surgical intervention and its literature review.

Keywords: Abdominal radiography, Foreign bodies, Laparotomy, Sexual orientation.

INTRODUCTION

The discovery of a sigmoid or rectal foreign body (RFB) is not something strange among surgical fraternity in the emergency department. The incidence varies in regions across the globe, however, it more often tends to involve the male gender of a wide range of age.¹ It has a bimodal age distribution; among the twenties for self-inflicted anal erotism and the sixties mainly for prostatic massage and breaking up faecal impactions.¹ All forms of a foreign body can be found from either organic (cucumbers, carrots, aubergine) or non-organic (plastic, rubber, wood, glass) types.^{1,2} Surgical attention will be

sought once the foreign body fails to be retrieved by the operator or causes harm to the body. Complications from the acts include intestinal obstruction when the mass causes total occlusion of the lumen, rectal or sigmoid perforation and haemorrhage due to excessive trauma.² Hereby, we describe a 25-year-old lady who inserted a foreign body into her rectum for sexual gratification which led to retention of the object resulting in lower abdominal pain and per-rectal bleeding.

CASE REPORT

A 25-year-old female presented to the emergency department at Indira Gandhi Memorial Hospital in the Republic of Maldives after having left lower colicky abdominal pain and blood-stained faeces per-rectally for a 1-day duration. She denied any history of trauma or

Correspondence: Dr Firdaus Hayati, General Surgeon, Department of Surgery, Faculty of Medicine and Health Sciences, Universiti Malaysia Sabah, Kota Kinabalu, Sabah, Malaysia
E-mail: firdaushayati@gmail.com

fall. She did not openly confess any transanal foreign body introduction. Upon assessment, the patient was vitally stable. The abdomen was soft without tenderness or peritonism. There was no mass palpated per abdomen. On the digital rectal examination, there was no active pre rectal bleed, but a hard object was felt at the tip of the finger.

An abdominal radiograph revealed a well-defined radiolucent structure in the pelvic region lying anterior to the sacrum (Figure 1a). The ascending and descending colon were not dilated. There was no air under the diaphragm which excluded any viscus perforation. Given the incongruent links between history and radiological findings, we had to inquire further for more information from the patient, especially on true but sensitive personal issues. Upon further inquiry, she confessed to having inserted a foreign body through her anus 2 days back. It was inserted for sexual pleasure but was unable to retrieve it after the act. As a radiological conclusion, correlating with the clinical history, this radio-

graph suggested a foreign body in the pelvic region likely represents a self-inserted foreign body in the rectum.

She was consented for manual retrieval under general anaesthesia with a possibility of conversion to midline laparotomy if that fails. Initial attempt at manual retrieval per rectum under general anaesthesia was unsuccessful. We proceeded to a lower mid-line laparotomy. Intraoperatively, there was a palpable mobile hard mass impacted in the sigmoid colon which was manually manipulated and successfully pushed down to be retrieved transanally (Figure 1b). There was no perforation nor peritoneal contamination noted. In the same setting, a concomitant intraoperative sigmoidoscopy was performed which showed mild areas of congestion in the rectosigmoid colon without mucosal defect. Postoperatively, she was well and was discharged home after 2 days. She was well on subsequent follow up in outpatient clinic.

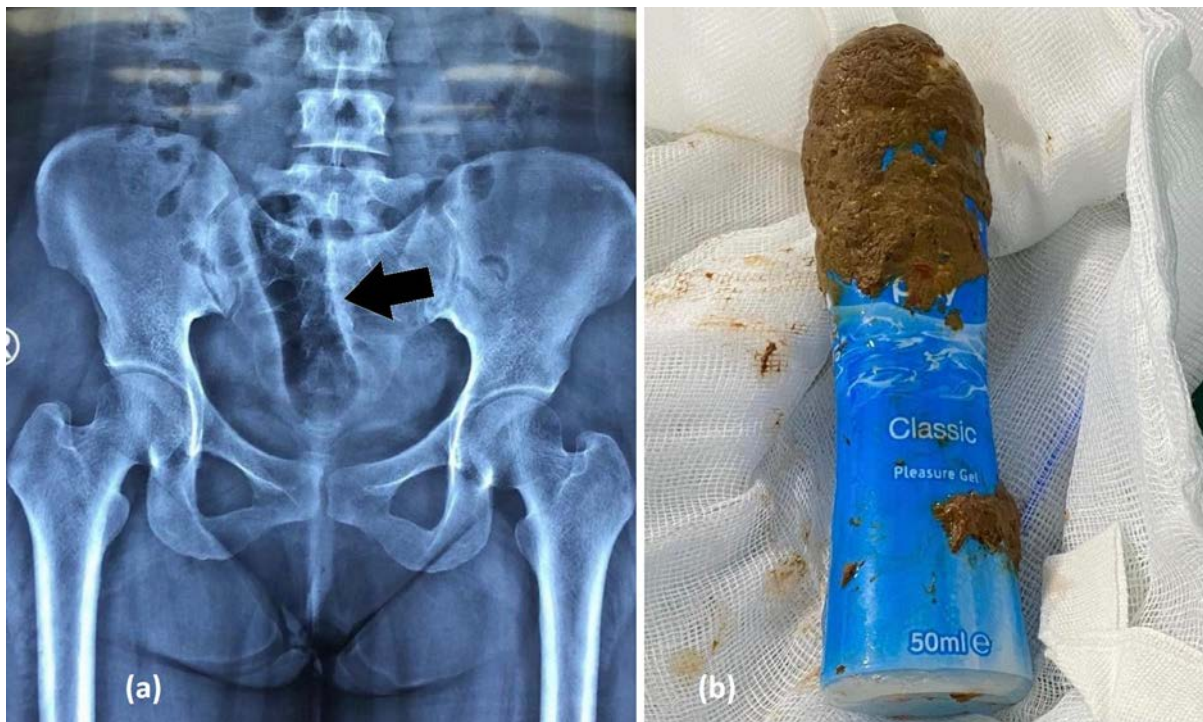


Figure 1: (a) Pelvic radiograph revealed a well-defined radiolucent structure in the pelvic region (black arrow), (b) The smooth penile-shaped plastic cannister which was retrieved from the rectum.

DISCUSSION

RFB may not be uncommon around the world with varying incidences in which the true number of reported cases may be lower than the expected events.¹ This could be due to patients' embarrassment towards the incidences thus they tend not to disclose the actual history of how it happened.² They only seek medical attention later when the foreign body causes complications after the failure of retrieval.

An academic way of classifying RFB based on Ali Coskun et al., is by categorising them into voluntary versus involuntary and sexual versus non-sexual type.³ The most commonly found cases of RFB are the objects that are inserted voluntarily for sexual stimulation and erotism. The foreign bodies used usually mimic the male genitalia in which they can be rubber adult sex toys, plastic or glass bottles, carrots, aubergine, and cucumbers. It is quite uncommon for females to be involved in rectal foreign bodies as mostly it occurs among males.¹ However, in our case, it involved female gender. Occasionally, there are cases of involuntary sexual foreign bodies that happen in rape, sexual assault or drunken state. These incidences are liable to a medicolegal aspect as a detailed sequence of events is required during the initial visit to the hospital. Local authorities need to be notified in the case of assault. The most common voluntarily non-sexual foreign body is best known as body packing and consists of illegal drug trafficking.⁴ Meanwhile, involuntarily non-sexual foreign bodies are generally found in children, the elderly and the mentally ill.⁴

Due to the distensibility of the sigmoid colon and rectum, complications such as perforation are quite rare. Unless the nature of the object inserted may predispose to bowel injury.³ Certain sharp instruments that are voluntarily or accidentally inserted into the sigmoid and rectum could cause bowel perforation.⁶ As a consequence, these patients

tend to present with peritonitis and septicaemia shock. Besides, the local impaction of foreign body in the sigmoid and rectum can lead to intestinal obstruction. The acts of frequent excessive insertion and removal of the RFB during anal erotism might cause mucosal abrasion and laceration wound, in which it will be manifested as per rectal bleeding. In our case, we suspect that there were components of colicky abdominal pain due to local impaction from the RFB and mucosal injury leading to per rectal bleeding.

Routine laboratory investigations are trivial, unless as per the requirement of pre-operative assessment. However, in cases of bowel perforation, septic markers are imperative. Abdominal imaging would be useful to assess the shape, nature, and location of the inserted object. The appearance of foreign bodies based on radiographs is either radio-paque or non-opaque in appearance. Examples of opaque foreign bodies include glass materials, most metallic materials except aluminium, most animal and some fish bones. Examples of non-opaque foreign bodies are most plastics, most aluminium objects, most wooden objects.⁶ Abdominal radiograph in a supine position is essential for initial diagnosis. In cases where the perforation is suspected, an abdominal radiograph in an erect position is mandatory to evaluate for pneumoperitoneum. Failure to prove via abdominal radiograph, computed tomography of the abdomen with water-soluble contrast is a sensitive tool in foreign body detection in cases where the foreign body is failed to visualise on radiographs and helps localise the site of the perforation.^{7,8} However, in peritonitis case, urgent laparotomy after resuscitation and stabilization is warranted.

Management of RFB depends on the clinical presentation, assessment, severity according to the American Association for the Surgery of Trauma, and intraoperative findings.⁹ Several techniques have been described

for the extraction of RFB.¹⁰ In low lying RFB, transanal extraction can be rendered with or without examination under anaesthesia, but the success rate is low.⁹ The retrieval can be undertaken by hand or forceps. In proximal RFB, endoscopic retrieval with flexible or rigid sigmoidoscopy is helpful. However, failure for minimally invasive surgery requires a step-up surgical approach especially among full thickness rectal injuries.¹¹ In partial thickness rectal injuries, non-operative intervention is needed unless full thickness injury is conclusively identified. Laparotomy with colotomy and transabdominal removal is warranted. In fact, in a tightly packed foreign body mimicking low rectal cancer requires more advanced decisions such as abdominoperineal resection.¹⁰ In our case, given an impacted and proximal migration of the foreign body, we had to proceed with laparotomy and intraoperative manipulation with transanal retrieval without breaching the bowel viscus.

CONCLUSION

A high index of suspicion is critical because history is frequently unreliable due to stigma around this sexual practice. Clinicians should always remember the RFB is always a possible aetiology for bowel obstruction, pelvic pain, bleeding per rectum, or intestinal perforation and have a low threshold for digital rectal examination and imaging because of the unreliable nature of the history for this problem. Surgery is warranted after the failure of minimally invasive or endoscopic treatment of RFB retrieval.

FINANCIAL DISCLOSURE OR CONFLICT OF INTEREST

The authors of this manuscript certify that there is no conflict of interest nor any financial interest in the subject matter or materials discussed in this manuscript. All authors have equal contribution to the case report.

CONSENT

We have acquired consent from patient for all images used in publication purpose.

REFERENCES

- 1: Kurer MA, Davey C, Khan S, Chintapatla S. Colorectal foreign bodies: a systematic review. *Colorectal Dis.* 2010;12(9):851-61.
- 2: Mohamad IS, Yaacob H. [An Aubergine in My ... Case of Rectal Foreign Body.](#) *Malays Fam Physician.* 2018;13(3):47-48. [Accessed on 31 May 2020].
- 3: Coskun A, Erkan N, Yakan S, et al. [Management of rectal foreign bodies.](#) *World J Emerg Surg.* 2013;8:11. [Accessed on 31 May 2020].
- 4: Goldberg JE, Steele SR: Rectal foreign bodies. *Surg Clin N Am.* 2010, 90: 173-184. 10.1016/j.suc.2009.10.004.
- 5: Cologne KG, Ault GT. [Rectal foreign bodies: what is the current standard?](#) *Clinics in colon and rectal surgery.* 2012;25(4):214-218. [Accessed on 31 May 2020].
- 6: Tim B. Hunter and Mihra S. Taljanovic. [Foreign bodies.](#) *Radio Graphics.* 2003;23:731-757. [Accessed on 31 May 2020].
- 7: Eliashar R, Dano I, Dangoor E, Braverman I, Sichel JY. Computed tomography diagnosis of esophageal bone impaction: a prospective study. *Ann Otol Rhinol Laryngol.* 1999;108:708-710.
- 8: Yap P, Hayati F, Sahid NA, et al. A lesson to learn in an iatrogenic perforation of sigmoid volvulus after endoscopic derotation. *Gazi Med J.* 2019;30:212-4.
- 9: Moore EE, Cogbill TH, Malangoni MA, et al. [Organ injury scaling, II: Pancreas, duodenum, small bowel, colon, and rectum.](#) *J Trauma.* 1990 Nov;30(11):1427-9. [Accessed on 31 May 2020].
- 10: Lee PP, Chuah JA, Sriram RK. [Unusual presentation of a rectal foreign body: a diagnostic dilemma.](#) *Int Surg J.* 2019;6(7):2587-2590. [Accessed on 31 May 2020].
- 11: Schellenberg M, Brown CVR, Trust MD, et al. Rectal Injury After Foreign Body Insertion: Secondary Analysis From the AAST Contemporary Management of Rectal Injuries Study Group. *J Surg Res.* 2020;247:541-546.